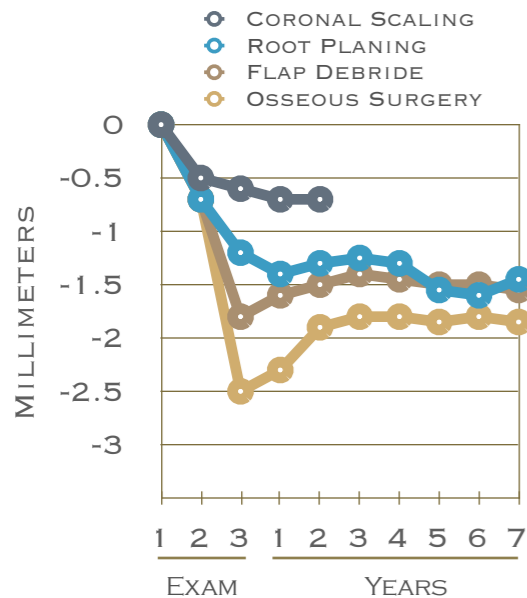


PROGNOSIS

The long term prognosis of the different forms of periodontal therapy are best summarized by a paper by Kaldahl et al from 1988. It compares four modalities of treatment: coronal scaling, root planing, flap debridement, and osseous surgery. Patients were followed for 7 years. The chart below demonstrates that the maximum benefit with regard to probing depth reduction was achieved through osseous surgery. However, regular 3 month periodontal maintenance after root planing is critical to maintain surgical progress, and was nearly as effective over time as surgical flap debridement, but not as effective as osseous surgery.

Prognosis is also dependent on good oral hygiene by the patient. In fact, surgery performed in the face of poor oral hygiene can actually worsen probing depths.

Regenerative therapy, not indicated in this graph, is the least predictable of the types of treatment, but can ultimately achieve the greatest pocket reduction.



SURGICAL VS NON-SURGICAL PERIODONTAL THERAPY

There are two primary modalities for the control of periodontitis, either non-surgical or surgical periodontal therapy. Non-surgical therapy consists primarily of scaling and root planing, as well as the use of local or systemic antibiotics or occlusal adjustment to control periodontal infection and bone loss.

Although skilled non-surgical therapy is highly effective for pocket reduction, occasionally probing depths do not resolve. Reasons for this include local impedance such as difficult tooth root anatomy or furcation involvement, enamel pearls or projections, overhanging restorations, difficulty in access, or poor oral hygiene on the part of the patient. Systemic factors include tobacco smoking, uncontrolled diabetes, stress and hormonal changes, clenching or grinding, certain medications, poor nutrition, and genetics.

When non-surgical therapy falls short, surgical therapy is recommended. There are three main types of surgical periodontal therapy: Flap debridement, Osseous Surgery, and Regenerative Surgery. These treatments are aimed at cleaning the root surface which was inaccessible through scaling only, and if possible, rebuilding lost bone.

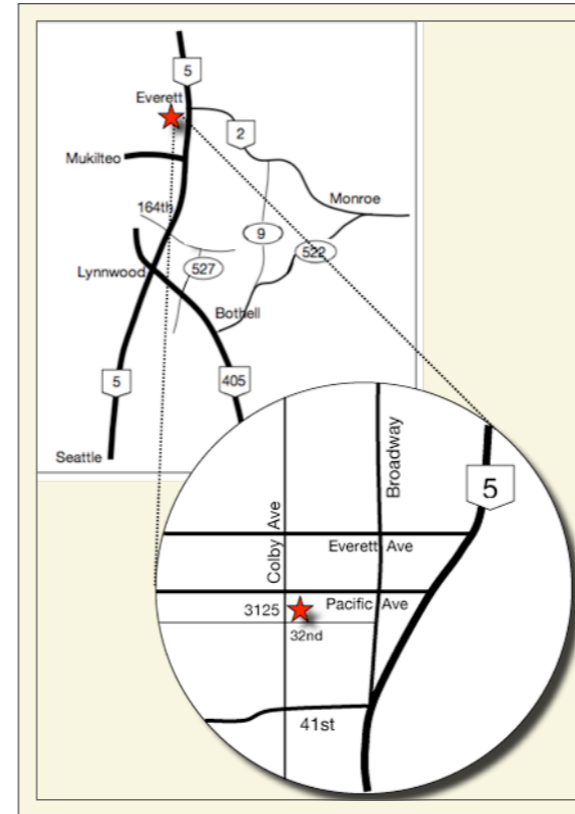
Please enjoy this issue of **ProbeTips** which will review the types of surgical periodontal therapy as well as the long term prognosis for treatment.

Copyright 2012 Dr. Pamela Nicoara

All cases are patients of Dr. Pamela Nicoara unless otherwise specified.

Pamela A Nicoara DDS MSD PLLC

PERIODONTOLOGY IMPLANTOLOGY ORAL MEDICINE



3125 Colby Avenue, Suite H
Everett WA 98201
T: 425-374-5380 F: 425-374-5382

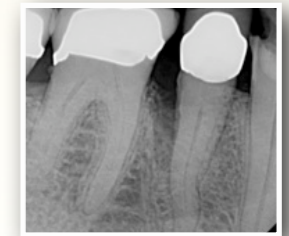
www.NICOARAPERIO.com
doctor@NICOARAPERIO.com

PROBE TIPS

A QUARTERLY PERIODONTAL
NEWSLETTER

BY PAMELA NICOARA DDS MSD

Surgical Treatment of Periodontitis



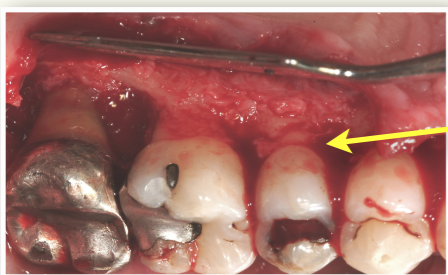
VOLUME 5, No. 3

NOVEMBER 2012

Surgical Treatment of Periodontitis

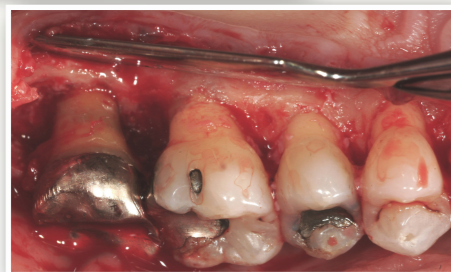OSSEOUS SURGERY

When initial conservative therapy in the form of scaling and root planing does not resolve probing depths 6mm or greater, surgical intervention is necessary. One of the most traditional ways of accomplishing this is to resect excess gingiva and expose the underlying bone to level out the areas of bone loss. Case 1 below demonstrates creating a positive bony architecture, as shown in the in the 'after' picture, through scalloping the bone to match the ideal natural gingival contours. This treatment works best for probings in the 5-7mm range. When probings are deeper, too much bone would need to be removed in order to create a more positive architecture, and may reduce enough support on the tooth that mobility and eventual tooth loss is a consequence. The disadvantage to this surgery is the resultant root exposure which often leads



Case 1
Before
Irregular
bone levels

After
Scalloped
'natural'
bone levels



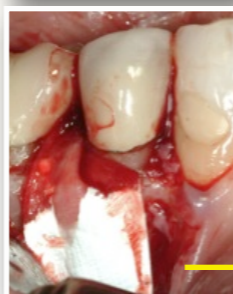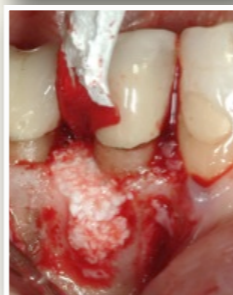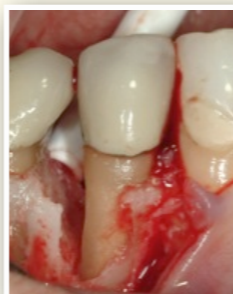to significant temperature sensitivity. In addition, this type of surgery is usually reserved for the teeth in the back of the mouth where esthetics is not as important as in the front of the mouth.

REGENERATIVE SURGERY

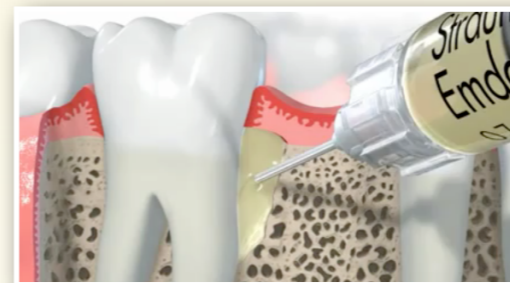
Sometimes the pattern of bone loss around a tooth is such that resecting the gingiva and bone is not the best option, and a regenerative approach is recommended. Guided Tissue Regeneration (GTR) can rebuild the previously lost bone surrounding a tooth. This process usually involves a bone graft and a membrane, and requires at least one existing wall of native bone to be successful in any way. The more walls of bone and the deeper the defect, the higher the success rate, provided there is no apical involvement.

The bone graft used is either taken intraorally, or more commonly from an outside source to avoid additional incisions and sutures. Membranes placed to keep the particulate in place are usually resorbable, rather than non-resorbable, since there are usually enough bony walls to support the graft (see adjacent).

The radiographs show the graft in place.

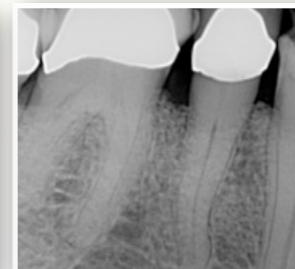
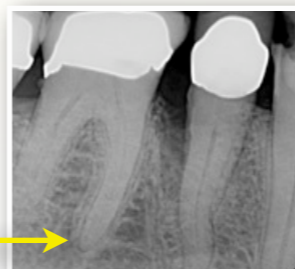

Regenerative procedures can also involve the use of bioactive gels, such as Emdogain. Emdogain acts as a 'fertilizer' to help the bone heal against the tooth and rebuild the lost tissues which do not easily form on their own. It can be mixed with the bone graft, or used during flap debridement if a bone graft is not possible.



FLAP DEBRIDEMENT

Of the three forms of surgical treatment, flap debridement provides a means of treating deep pockets that cannot be regenerated, but where removing soft tissue or bone is also prohibited. Maxillary molar teeth are an excellent example of this: where there is an exposed furcation which is inaccessible to proper debridement for regeneration, and which is deep enough not to want to remove more bone. Flap debridement is essentially a glorified deep cleaning, with greater



access. The advantage to this type of surgery is most useful for treating anterior teeth where a deep pocket may not have enough bony walls for regeneration, and we do not want to cause an esthetic dilemma by removing significant amounts of soft tissue.

ADDITIONAL TREATMENT

Antibiotics: If periodontal infection is severe or widespread, or anytime a bone graft is used, antibiotics are recommended to help control the growth of bacteria that create toxins and prevent normal healing after surgery.

Occlusal Adjustment: Adjusting the biting surfaces of the teeth can help alleviate excessive forces on a particular tooth or group of teeth which are loose, preventing further bone loss or bone regeneration. In other instances, a grinding habit may be wearing down the surfaces of the teeth. Fabrication of a custom bite guard can help to control how pressure is distributed on the teeth and will protect teeth and restorations from further wear or replacement, or even tooth loss.

REFERENCES

- J Perio.* Kaldahl et al. 1988.
- JCP.* Serino et al 2001.
- JCP.* Palmer and Cortellini. 2008.
- Perio 2000.* Bosshardt and Sculean 2009.
- Perio 2000.* Deas and Mealey. 2010.

complete references available on request
Copyright 2012 Dr. Pamela Nicoara